



OPEN

Indications, feasibility and outcome of robotic retroperitoneal lymph node dissection for metastatic testicular germ cell tumours

Carsten-Henning Ohlmann^{1,2,3}, Matthias Saar^{1b2}, Laura-Christin Pierchalla¹, Miran Zangana², Alena Bonaventura², Michael Stöckle², Stefan Siemer² & Julia Heinzlbecker^{1b2✉}

Data on robotic retroperitoneal lymph node dissection (R-RPLND) for metastatic testicular germ cell tumours (mTGCTs) are scarce and the use of R-RPLND itself is still under debate. The aim of our study was to evaluate the indications, feasibility and outcomes of R-RPLND, with special emphasis on differences between primary R-RPLND (pR-RPLND) and post-chemotherapeutic R-RPLND (pcR-RPLND) in mTGCTs. We retrospectively analysed the data of patients who underwent R-RPLND for mTGCT between November 2013 and September 2019 in two centres in Germany. Indications, operative technique, intra- and postoperative complications and oncologic outcome were analysed. Twenty-three mTGCT patients underwent R-RPLND (7 pR-RPLND, 16 pcR-RPLND). For pR-RPLND versus pcR-RPLND, median time of surgery was 243 min [interquartile range (IQR) 123–303] versus 359 min (IQR 202–440, $p = 0.154$) and median blood loss 100 mL (IQR 50–200) versus 275 mL (IQR 100–775, $p = 0.018$). Intra- and postoperative complications were more frequent in pcR-RPLND (pcR-RPLND: intra/post: 44%/44%; pR-RPLND: intra/post: 0%/29%). However, these were only statistically significant in the case of intraoperative complications (intra: $p = 0.036$, post: $p = 0.579$). Intraoperative complications ($n = 7$), conversions ($n = 4$) and transfusions ($n = 4$) occurred in pcR-RPLND patients only. After a median follow-up of 16.3 months (IQR 7.5–35.0) there were no recurrences or deaths. R-RPLND displays a valuable, minimally invasive treatment option in mTGCT. However, R-RPLND is challenging and pcR-RPLND especially bears a considerable risk of complications. This operation should be limited to patients with an easily accessible residual tumour mass and to surgeons experienced in robotic surgery and TGCT treatment.

Testicular germ cell tumours (TGCTs) affect young men, but the disease itself has an excellent cure rate¹. Retroperitoneal lymph node dissection (RPLND) is an important column of TGCT treatment, though it has a shrinking importance in clinical stage (CS) 1^{2–5}. Nevertheless, in metastatic TGCT (mTGCT), RPLND remains an integral part of treatment in both the primary (p) and post-chemotherapeutic (pc) setting^{2,4}. To date, RPLND is mainly performed by open surgery, and has ever since been associated with a relatively high complication rate⁶. With the introduction of minimally invasive surgery, promising results were achieved with laparoscopic RPLND (L-RPLND)^{7,8}. Due to the technical advantages of robotic surgery, several groups started to transfer the results of L-RPLND into robotic RPLND (R-RPLND)^{9–12}. Since the beginning of the development of minimally invasive RPLND, concerns have been raised, mainly in terms of perioperative morbidity and oncologic outcome^{7,13}. It is apparent that a minimally invasive approach can only be called successful if its advantages are not outweighed by perioperative morbidity and oncologic outcomes.

We thus evaluated the indications, feasibility and outcomes of R-RPLND in mTGCT, with special emphasis on differences between pR-RPLND and pcR-RPLND.

¹Department of Urology, Malteser Krankenhaus Seliger Gerhard, Bonn, Rhein-Sieg, Germany. ²Department of Urology and Paediatric Urology, Saarland University Medical Centre and Saarland University Faculty of Medicine, Homburg, Saar, Germany. ³Present address: Department of Urology, Johanniter Krankenhaus, Bonn, Germany. ✉email: julia.heinzlbecker@uks.eu

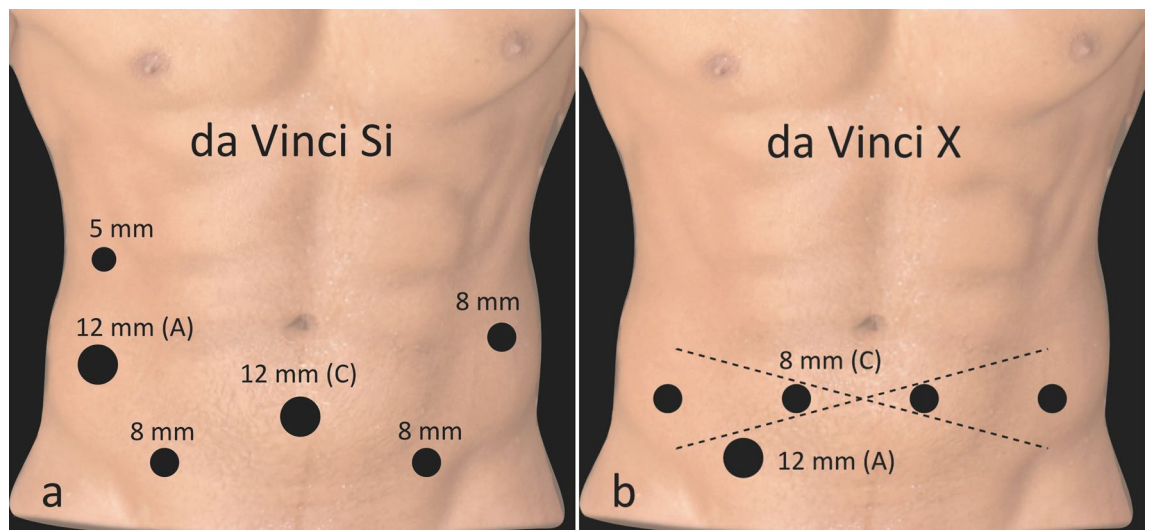


Figure 1. Port placement. **(a)** Da Vinci Si: Port placement included three 8-mm trocars—two above the anterior superior iliac spine on each side and a third one approximately 8 cm cranially on the left side underneath. The camera trocar (12 mm) was placed in the midline, 5 cm below the umbilicus, in line with the two 8-mm trocars. For the assistant physician, a 12- and 5-mm trocar was inserted on the right side below the costal arch. Port placement was the same for unilateral and/or bilateral cases. **(b)** Da Vinci X: Port placement included four 8-mm da Vinci trocars, including the 8-mm camera trocar (right lower abdomen), inserted in one line in the lower abdomen with equivalent distances to each other. For the assistant physician, a 12-mm trocar was inserted in the right lower abdomen, even more caudal to the da Vinci trocars. If a unilateral modified template is dissected, this approach can be modified according to Stepanian et al., with the line of the robotic trocar placement turning towards the aimed template²⁴. We thank Thomas Gebhardt for creating the figure.

Patients and methods

Patient population.

We retrospectively analysed the records of all patients who underwent R-RPLND for mTGCT between November 2013 and September 2019 at the Urology Departments of Saarland University Medical Centre, Homburg [n = 18, 11/2013–09/2019, open RPLND: n = 9 (33%)], and Malteser Hospital, Bonn, a teaching hospital of the University Hospital Bonn [n = 5, 07/2018–08/2019, open RPLND: n = 0 (0%)]. Patients were offered R-RPLND in case of limited retroperitoneal disease and when appearing technically feasible according to preoperative imaging. All patients gave written informed consent and anonymized patient data were used. This proceeding was approved by with the ethics committee of Saarland (identification number: 135/20). All methods were performed in accordance with the relevant guidelines and regulations. Each indication for R-RPLND was thoroughly approved according to guidelines, histological findings, clinical stage and patient compliance. Staging of the patients was performed according to the current TNM and IGCCCG classifications^{1,14}. In pcR-RPLND patients, standard frontline chemotherapy regimens included bleomycin/etoposide/cisplatin (n = 14) or cisplatin/etoposide/ifosfamide (n = 2, due to concerns on bleomycin because of heavy smoking and/or inhaling drug abuse).

Surgical technique.

Operations were performed by five experienced surgeons (C.-H.O., S.S., J.H., M.S., M.S.) for open and robotic RPLND. C.-H.O. and S.S. took part in all operations, either as the primary surgeon or as supervisor.

The extent of RPLND depended on the primary site of metastasis. Modified RPLND template dissection was performed in patients with low-volume disease, limited to the primary landing zone of the affected testis^{15–17}. The right-sided template included the right common iliac, paracaval, precaval, retrocaval, and interaortocaval lymph nodes and the right gonadal vein; the left-sided template included the left common iliac, preaortic, para-aortic, and retroaortic lymph nodes to the level of the inferior mesenteric artery, and the left gonadal vein¹⁶. Low volume disease in pcR-RPLND patients was defined according to the extension of lymph node diameter after chemotherapy. In all other patients a bilateral, nerve-sparing (whenever possible) template was resected.

The da Vinci Si and X four-arm surgical systems (Intuitive Surgical, Palo Alto, California, USA) were used. A transperitoneal approach was applied. For trocar placement in the supine position see Fig. 1.

Afterwards, the patient was placed with the head downward and the legs slightly bent. In addition, the left side was rotated 15° downwards, with the system docked from the head of the patient over the left shoulder (Fig. 2).

Access to the retroperitoneum started with the mobilisation of the caecum and ileum by incision of the peritoneum. Thus, the colon and small intestines fell away from the operative field. With the third robotic arm the peritoneum was retracted. If necessary—i.e., in obese patients or at poor exposure—percutaneous stay sutures were placed to keep away the peritoneum¹⁸. After identification of the dissection field margins, the lymph nodes (LNs) were removed by the split-and-roll technique, starting from the caudal border at the crossing of the iliac artery and ureter¹⁹. Dissection then continued cranially with the precaval and pre-aortal LNs. Inter-aortocaval

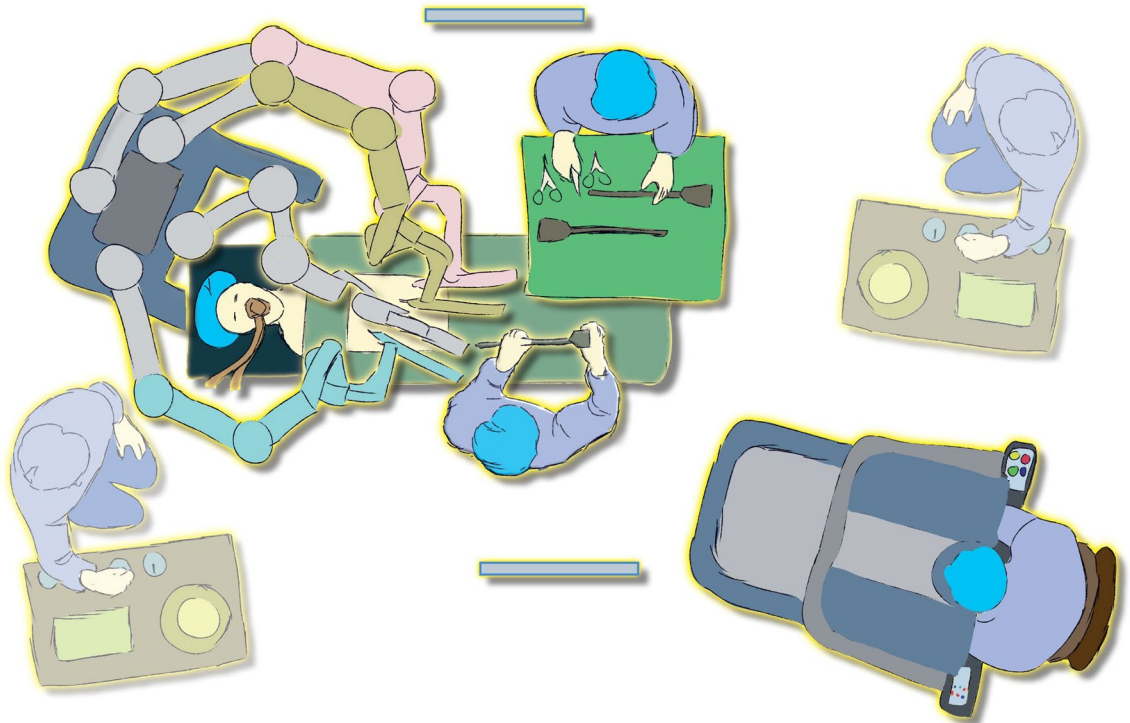


Figure 2. Operating room set-up for robotic retroperitoneal lymph node dissection (R-RPLND). We thank Thomas Gebhardt for creating the figure.

LN were mobilised, starting at the aortic bifurcation, where the sympathetic nerve fibres of the hypogastric plexus were identified and secured to achieve a nerve-sparing technique. After mobilisation of the descending colon, it was retracted by the assistant port. Para-aortic LNs above the inferior mesenteric artery (IMA) were easily accessed from the right side. Ligation and division of the IMA were only needed in selected cases. Access to the retrocausal and retroaortic LNs was achieved using vessel loops and a 30° optical lens. Dissected LN tissue of specified resection areas was removed using the 12-mm assistant port or non-permeable retrieval bags.

Assessment of complications and Follow-up. Intra- and postoperative complications were defined as any variation from the usual course. Postoperative complications were assessed using the Clavien–Dindo classification system²⁰. Patient follow-up was performed according to the recommendations of the European association of Urology². Relapse was defined as elevation of tumour markers or progressive disease on imaging.

Statistical analysis. Continuous variables are shown as medians with interquartile ranges (IQR), and categorical variables were assessed using frequencies and proportions. Differences between groups were calculated with the Mann–Whitney U test for continuous variables and with the Chi² test for categorical variables. A *p*-value of < 0.05 was considered statistically significant. Statistical analysis was carried out using SPSS 25 (IBM Corporation, Armonk, New York, USA).

Results

Baseline patient characteristics. A total of 23 mTGCT patients underwent R-RPLND. Thirteen were performed using the da Vinci Si platform and ten were performed using the X platform. Seven (30%) received pR-RPLND and 16 (70%) received pcR-RPLND. For baseline and preoperative characteristics, see Table 1.

Most of the patients were nonseminomatous TGCT (NSGCT) patients (78%), predominantly CS 2 (83%) with a good prognosis (70%). The main indication for R-RPLND in mTGCT was pc residual mass. All patients had normalised tumour markers (AFP, β-HCG, LDH) prior to R-RPLND.

Two seminoma patients underwent pcR-RPLND; one due to life-threatening recurrent septic conditions during the first two of three planned cycles of chemotherapy, most probably associated to trisomy 21 (CS 2B patient)²¹; the other one due to a haemodynamic relevant compression of the inferior caval vein by the residual tumour (CS 2C).

Three patients relapsed under surveillance in CS 1, one seminoma and two NSGCT patients. Two of them (one seminoma, one NSGCT) relapsed with CS IIA (both marker negative) and were treated with pR-RPLND; the third patient (NSGCT) relapsed with CS IIB and was treated with chemotherapy. Because of residual tumour disease, he underwent pcR-RPLND afterwards. Three seminoma patients received pR-RPLND in CS 2A, two at primary diagnosis and one at relapse under surveillance. One NSGCT patient presented with late relapse at

Patients n = 23	pR-RPLND n = 7	pcR-RPLND n = 16
Median age, year (IQR)	43 (23–46)	32 (26–45)
Median BMI, kg/m ² (IQR)	27.2 (19.9–35.3)	27.8 (23.4–31.8)
ASA Score, n (%)		
I	3 (43)	5 (31)
II	4 (57)	10 (63)
III	0 (0)	1 (6)
IV, V	0 (0)	0 (0)
Primary site of TGCT		
Left	3 (43)	10 (63)
Right	4 (57)	6 (38)
Primary tumour histology, n (%)		
NSGCT	4 (57)	14 (88)
Seminoma parts	5 (71)	8 (50)
Teratoma parts	4 (57)	9 (56)
Yolk sac tumour parts	2 (29)	7 (44)
Embryonal cell carcinoma parts	2 (29)	13 (81)
Chorioncarcinoma parts	0 (0)	3 (19)
Seminoma	3 (43) ^a	2 (13) ^b
Clinical stage, n (%)		
2A ^c	7 (100)	1 (6)
2B	0 (0)	8 (50)
2C	0 (0)	3 (19)
3A	0 (0)	1 (6)
3B	0 (0)	2 (13)
3C	0 (0)	1 (6)
IGCCCG classification, n (%)		
Good	7 (100)	9 (56)
Intermediate	0 (0)	5 (31)
Poor	0 (0)	2 (13)
Median largest tumour diameter at R-RPLND, cm (IQR)	1.7 (1.4–1.9)	2.3 (1.8–4.0)

Table 1. Baseline characteristics of patients prior to R-RPLND. *yr* years, *IQR* interquartile range, *BMI* body mass index, *ASA* American Society of Anaesthesiologists, *TGCT* testicular germ cell tumour, *NSGCT* nonseminomatous germ cell tumour, *IGCCCG* International Germ cell Cancer Collaborative Group, *R-RPLND* robotic retroperitoneal lymph node dissection, *pR-RPLND* primary robotic retroperitoneal lymph node dissection, *pcR-RPLND* post-chemotherapeutic robotic retroperitoneal lymph node dissection. ^aTwo seminoma patients received pR-RPLND in CS 2A and one patient in CS 2A at relapse under surveillance. They either denied radiotherapy/chemotherapy or R-RPLND was performed to gain diagnostic accuracy. The patient at relapse in CS 2A was upgraded to CS 2B (pN2) disease after R-RPLND. Of the two other patients only one had a vital seminoma metastasis (CS 2A, pN1), the other patient was downgraded to CS 1 disease. None of them received further adjuvant treatment and all of them are recurrent free and alive at a median follow-up of 12 (IQR 10–18) months. ^bTwo seminoma patients received pcR-RPLND: one trisomy 21 patient because of life-threatening intolerance to chemotherapy in CS 2B with only two cycles of chemotherapy being administrable and one in CS 2C with haemodynamic relevant compression of the inferior caval vein due to the residual tumour mass. In both cases histology revealed necrosis only. ^cOne NSGCT patient presented with relapse in the retroperitoneum of less than 2 cm 5.2 years after diagnosis of CS 1S disease treated initially with three cycles of chemotherapy. This patient was comprised in the CS 2A and pcR-RPLND patients. Final histology revealed a teratoma and was classified as ypN2 disease.

5.2 years after chemotherapy for CS 1S disease with a less-than-2-cm mass in the retroperitoneum. All were marker-negative at R-RPLND.

Perioperative outcome. In most of the patients, a unilateral modified template was performed (n = 14 (61%)). The median tumour diameter at R-RPLND was 1.9 cm (IQR 1.7–3.3). Fifteen patients (65%) underwent nerve-sparing procedures. For perioperative outcomes, see Table 2.

Median operation time was 303 min (IQR 195–435) in all cases, with 243 min (IQR 123–303) and 359 min (IQR 202–440) for pR-RPLND and pcR-RPLND (p = 0.154). Median estimated blood loss was 200 mL (IQR 100–450), being significantly higher in pcR-RPLND, with 275 mL (IQR 100–775) compared to 100 mL (IQR 50–200) in pR-RPLND (p = 0.018). Four patients (17%) received blood transfusions (all pcR-RPLND).

Patients n (%)	Overall 23 (100)	pR-RPLND 7 (30)	pcR-RPLND 16 (70)	p-value
Median operation time, min (IQR)	303 (195–435)	243 (123–303)	359 (202–440)	0.154
Median EBL, ml (IQR)	200 (100–450)	100 (50–200)	275 (100–775)	0.018*
Resection template, n (%)				
Bilateral	8 (35)	0 (0)	8 (50)	0.039*
Unilateral modified	14 (61)	7 (100)	7 (44)	
Lumpectomy ^a	1 (4)	0 (0)	1 (6)	
Nerve-sparing, n (%)				
Yes	15 (65)	6 (86)	9 (56)	0.172
No	8 (35)	1 (14)	7 (44)	
Median nodal yield, n (IQR)				
Bilateral	26 (12–30)	na	26 (12–30)	0.49
Unilateral modified	12 (8–27)	11 (6–17)	8 (8–16)	
Lumpectomy ^a	1 (na)	na	1 (na)	
Lesion histology, n (%)				
Necrosis or normal tissue	8 (25)	2 (29)	6 (38)	ne
Teratoma	6 (26)	1 (14)	5 (31)	
Germ cell tumour	9 (39)	4 (57)	5 (31)	
Final nodal stage, n (%)				
pN0	8 (35)	2 (29)	6 (28)	0.298
pN1	7 (30)	1 (14)	6 (38)	
pN2	8 (35)	4 (57)	4 (25)	
pN3	0 (0)	0 (0)	0 (0)	
Complication rate, n (%)				
Intraoperative	7 (30)	0 (0)	7 (44)	0.036*
Postoperative ^b	9 (39)	2 (29)	7 (44)	0.493
Intraoperative complications				
Bleeding lumbar artery	1	na	1	
Partial resection of ureter	1	na	1	
Partial resection of ileum	1	na	1	
Poor exposure	2 (→ conversion)	na	2 (→ conversion)	
Ventilation problems	1 (→ conversion)	na	1 (→ conversion)	
Bleeding renal vein, nephrectomy	1 (→ conversion)	na	1 (→ conversion)	
Clavien-Dindo Classification^b, n (%)				
I	0	0	0	
II bleeding with blood transfusion ^c	4	0	4	
IIIa chylous ascites	1	1	0	
lymphocele	4	1	3	
IIIb wound dehiscence ^d	1	0	1	
Compartment syndrome left leg ^d	1	0	1	
Chylous ascites	1	0	1	
IVa	0	0	0	
IVb	0	0	0	
Conversion rate, n (%)	4 (17)	0 (0)	4 (25)	0.146
Transfusion rate, n (%)	4 (17)	0 (0)	4 (25)	0.146
Length of stay, days (IQR)	6 (4–9)	4 (4–9)	6 (5–10)	0.376
Median follow-up, months (IQR)	16.3 (7.5–35.0)	11.5 (7.0–27.4)	19.2 (7.9–35.0)	0.492

Table 2. Peri- and postoperative patient outcome. *pR-RPLND* primary robotic retroperitoneal lymph node dissection, *pcR-RPLND* post-chemotherapeutic robotic retroperitoneal lymph node dissection, *n* patient number, *IQR* interquartile range, *EBL* estimated blood loss, *na* not applicable, *ne* not evaluated. *Statistically significant $p < 0.05$. ^aLumpectomy was performed in one patient with hemodynamic relevant compression of the caval vein by residual tumour of a seminoma. ^bComplications within 90 d postoperatively according to Clavien–Dindo Classification. ^cThree of them converted patients. ^dConverted patient.

Intraoperative complications occurred only in pCR-RPLND patients ($n=7$, 30% compared to $n=0$, 0%) ($p=0.036$). Of them, three were successfully managed robotically—bleeding of a lumbar artery (without indication for transfusion), partial resection of the left ureter by performing an end-to-end anastomosis and partial resection of the ileum by establishing an end-to-end anastomosis. Ureteral injury was due to tumour involvement and bowel injury occurred iatrogenic due to thermal injury. In four cases, conversion to open surgery was decided upon. Adhesion of tumour tissue to the renal vein was managed by nephrectomy to prevent further blood loss and enabling complete resection of residual tumour tissue. In two of the first patients, poor exposure of the retroperitoneum led to conversion. In another patient with large-volume CS 3A disease, anaesthetic ventilation problems marked by subsequently rising pulmonary pressure due to the pneumoperitoneum forced late conversion after prolonged operation time.

Postoperative complications occurred in nine patients (39%), of whom seven (30%) had major complications (Clavien–Dindo \geq III; Table 1)—two (29%, all major) patients of the pR-RPLND and seven (44%, five major) of the pCR-RPLND group ($p=0.493$). The most frequent major complications were chylous ascites and lymphoceles. Most of them could be managed by placing a drainage under local anaesthesia. However, in one patient chylascites had to be treated by open surgical ligation of the thoracic duct. In two other patients, grade IIIb complications occurred—a secondary wound dehiscence in one and a compartment syndrome of the left lower leg in another patient, both managed with surgery. Median length of stay was 6 days (IQR 4–9), with four days (IQR 4–9) in the pR-RPLND and 6 days (IQR 5–10) in the pCR-RPLND patients ($p=0.376$).

Oncologic outcome and follow-up data. On pathological review, the median nodal yield was 11 (IQR 7–26); 26 (IQR 12–30) in bilateral and 12 (8–27) in modified unilateral resected templates. The most frequent histology was germ cell tumour (GCT) in nine (39%) patients, with GCT ($n=4$, 57%) being the most frequent histology type in the pR-RPLND and necrosis ($n=6$, 38%) being the most frequent in the pCR-RPLND patients. Eight patients (35%) had no metastatic lesions (pN0), seven (30%) were classified as pN1 and eight (35%) were classified as pN2. In pR-RPLND patients, two (29%) were downgraded to pathological stage (PS) 1 disease, one seminoma and one NSGCT patient. Four (57%) of the pR-RPLND patients were upgraded from CS 2A to PS 2B (pN2) disease, two seminoma and two NSGCT patients (R-RPLND: teratoma; embryonal cell carcinoma). In none of the cases was adjuvant treatment performed. All patients had negative postoperative tumour markers. At a median follow-up of 16.3 months (IQR 7.5–35.0) there were no recurrences or deaths in any patients (see Table 2).

Discussion

The use of minimally invasive RPLND is still under debate, as concerns regarding morbidity and oncologic efficacy exist. Compared to open RPLND, minimally invasive RPLND has the advantage of lower blood loss, less pain, shorter length of stay and cosmetic benefits^{7–10,12,22}. However, laparoscopic RPLND is challenging and therefore R-RPLND, with its technical benefits, may overcome the limitations of laparoscopic RPLND.

To date, most of the studies on R-RPLND have reported on pR-RPLND^{10,18,22–25}, with the largest cohort comprising 58 patients including mainly CS 1 tumours²². Only a few publications on pCR-RPLND are available^{11,12,26,27}, with the largest series comprising 45 patients²⁷. So far, only one other publication exists on R-RPLND in a mere mTGCT patient collective, comprising both pR-RPLND ($n=22$) and pCR-RPLND ($n=4$) patients²⁸. Such reports define the possibilities of R-RPLND for mTGCT patients, taking into account the nearly vanished relevance of pR-RPLND in CS 1 patients, in whom the treatment options nowadays are surveillance or one cycle of chemotherapy in high-risk patients^{2,3,5}. Additionally, no direct comparison between pR-RPLND and pCR-RPLND in mTGCT has been made. In the present study, it became evident that pR-RPLND and pCR-RPLND for mTGCT may be challenging in different ways. The results of our series of patients demonstrate the feasibility of R-RPLND for a wide range of indications, as well as the differently challenging character of pR-RPLND compared to pCR-RPLND, with acceptable morbidity and excellent early oncologic efficacy in mTGCT patients.

Positioning of the patient and trocars is crucial for optimal exposure, with poor exposure being the most frequent reason for conversions in the beginning of our series. We used an approach with the patient in the supine position. Alternative positioning included patient in the flank^{10–12} or lower lithotomy position¹⁸, with the limitation that only unilateral or modified template resection was possible. The positioning of the patient in the supine position, with all of the trocars placed in the lower abdomen, offers ideal access to the retroperitoneum, enabling both uni- and bilateral template resection²⁴. Using this approach, R-RPLND has a broad range of indications in mTGCT, ranging from patients primarily presenting CS 2A/B disease to those at relapse under surveillance and those with residual disease after chemotherapy, all of whom were included in our analysis.

With a median estimated blood loss of 200 mL, our study demonstrates the minimally invasive nature of the technique^{12,22}. A median time of surgery of 303 min—243 in pR-RPLND and 359 in pCR-RPLND—seems to be quite long, however is comparable to the results of others^{12,22}.

When comparing the pR-RPLND with the pCR-RPLND patient collective, we observed a higher operating time, conversion rate, blood loss, transfusion rate and complication rate in the pCR-RPLND patients. In terms of statistical significance, only blood loss was higher and intraoperative complications occurred more frequently in the pCR-RPLND patients. A direct comparison of pR-RPLND and pCR-RPLND is not available to date. Rocco et al. reported an intra- and postoperative complication rate of 3.3% and 33%, respectively, in mainly CS 1 pR-RPLND patients²². This is in line with our complication rates, which were 0% for intra- and 29% for postoperative complications in the pR-RPLND group. pCR-RPLND is challenging even in open surgery, and bears the risk of intraoperative complications and additional procedures⁶. Li et al. reported an overall postoperative complication rate of 32%, including 19% major complications for both pCR-RPLND and open RPLND¹². In total, 20% (10% major) of the complications occurred in pCR-RPLND, and 40% (24% major) in open RPLND patients.

Other large open RPLND series report on 18% major postoperative complications with vascular injury being the most common intraoperative and ileus the most frequent postoperative complication²⁹. We report a higher overall postoperative complication rate of 39% (30% major), comprising both pR-RPLND and pcR-RPLND. The most common major postoperative complications in our series were chylous ascites (8%) and lymphoceles (17%) that in most cases were easily managed by putting in a drainage. Large studies on open pc-RPLND report lower lymphocele rates compared to chylous ascites rates of 3% vs. 13%, with chylascites being the second most frequent general postoperative complication²⁹. Thus patients should be informed about these important complications preoperatively. In our series all intraoperative complications, conversion to open surgery and major postoperative complications (Clavien–Dindo $\geq 3b$) occurred during the first three years after implementation of the technique and in the pcR-RPLND collective only, illustrating that a learning curve is relevant. Thus even in a high volume robotic surgery centre (>600 robotic procedures per year) a learning curve of R-RPLND has to be taken into account. Furthermore these results demonstrate that pcR-RPLND is more challenging than pR-RPLND. Thus, especially at the implementation of the technique, one has to bear a higher complication rate in mind, and starting in patients with limited disease seems reasonable. In summary our results are in line with the results of other large volume series on R-RPLND^{22,27,28}.

Tumour size in the retroperitoneum is the most important challenging factor in open pc-RPLND³⁰. This might even be more relevant for R-RPLND. According to our experience, patients with limited disease in the retroperitoneum are ideal candidates for R-RPLND. The altered desmoplastic tissue after chemotherapy and the differences in seminoma and NSGCT histology are additional challenging reasons, even in open RPLND³¹. However, although limited to two patients, our results demonstrate that pcR-RPLND in special indications is feasible even in seminoma patients.

Minimally invasive RPLND series have been criticised for incomplete template dissection. With our positioning of the patient in the supine position, all relevant template resections, even bilateral templates, are possible. Our median nodal yield was 11, 26 in bilateral and 12 in modified unilateral templates, which is lower than that described in other studies^{10,12,22}. This may be due to the wide variation in indications and resected templates. Furthermore, postchemotherapeutic tumours are often large convoluted masses, making nodal count in this setting not reliable and highly dependent on the pathologists expertise³². Concerning pR-RPLND, there are no reliable studies on retroperitoneal nodal counts in healthy patients. Additionally, we did not perform a pathologic re-review. Traditionally, a wide variation in lymph node yields exists, depending on whether they are performed en bloc or in packages and how pathology processing and specimen evaluation are performed³².

The results reported by Calaway et al. should attract attention³³. They report on five patients that were referred to their department after R-RPLND elsewhere, all presenting with recurrences in unusual locations. Reasons for this, such as poor patient selection, poor operative technique and surgical technology, are discussed. The median time to recurrence was 259 days (range 92–503). In our own series, with a median follow up of 495 days (IQR 251–933), we have so far seen no recurrences or deaths. Nevertheless, our results need to be validated with a longer follow-up period.

As indications for pR-RPLND in CS 1 disease, due to the nowadays most often applied treatment options of surveillance or one cycle of chemotherapy, have almost vanished, our study shows the wide indications for R-RPLND in mTGCT in a real-world setting^{2,3,5}. Of note, several patients with special indications were included—seminoma patients in CS 2A, patients at relapse under surveillance, a patient at late relapse after chemotherapy and pc seminoma patients. Of the pR-RPLND mTGCT patients, three were seminomas in CS 2A disease. All of these patients denied radiation or chemotherapy, and with the aim of offering an approach that reduces toxicities and overtreatment and, in response to the setting of the SEMS and PRIMETEST trials, pR-RPLND was performed^{34–37}. All of these patients were discharged after three to four days. None of them received adjuvant treatment and all of them are relapse free at 24, 12 and 9 months, respectively. Even though these results need confirmation with longer follow-up and in a prospective setting, they show the possibilities of pR-RPLND in mTGCT patients, holding the promise of sparing adjuvant therapies, providing excellent oncologic outcomes and at the same time offering a minimally invasive therapy approach^{5,38,39}.

Concerning pc-RPLND, as reliable prognostic markers for residual disease in RPLND specimens are still lacking, we are overtreating up to 40–50% of pc TGCT patients¹⁶. Thus the extent of the dissection and its morbidity should be as limited as possible^{40,41}. This can be achieved with a robot-assisted approach and a limited dissection template⁴¹.

There are several limitations to our study, including its retrospective character, the missing evaluation of antegrade ejaculation and the pathologic re-evaluation of the number of lymph nodes dissected. Additionally, different surgeons were involved in the operations. A larger series and a longer follow-up are needed to further determine the role of R-RPLND in mTGCT.

Conclusion

R-RPLND offers a treatment option for mTGCT in both the primary and post-chemotherapeutic setting. pR-RPLND in mTGCT displays a minimal-invasive treatment option whilst sparing adjuvant therapies associated with mortality increasing long-term toxicities. Pc-RPLND is associated with a 40–50% chance of overtreatment. The robotic approach offers a minimal-invasive treatment alternative to these patients. PcR-RPLND is more challenging than pR-RPLND. Both, pR-RPLND as pcR-RPLND, are providing excellent oncologic outcome in the mTGCT patient setting. Carefully chosen mTGCT patients, in the hands of surgeons experienced in TGCT treatment and robotic surgery, may profit from minimally invasive R-RPLND.

Received: 3 November 2020; Accepted: 30 April 2021

Published online: 21 May 2021

References

- International Germ Cell Cancer Collaborative Group. International Germ Cell Consensus Classification: A prognostic factor-based staging system for metastatic germ cell cancers. *J. Clin. Oncol.* **15**, 594–603 (1997).
- Laguna, M. P. *et al.* Guidelines on testicular cancer. In *EAU Guidelines* vol. Edn. presented at the EAU Annual Congress Amsterdam 2020 (EAU Guidelines Office, 2020).
- Kliesch, S. *et al.* Management of germ cell tumours of the testis in adult patients german clinical practice guideline part I: Epidemiology, classification, diagnosis, prognosis, fertility preservation, and treatment recommendations for localized stages. *Urol. Int.* <https://doi.org/10.1159/000510407> (2021).
- Kliesch, S. *et al.* Management of germ cell tumours of the testes in adult patients: German clinical practice guideline, PART II—Recommendations for the treatment of advanced, recurrent, and refractory disease and extragonadal and sex cord/stromal tumours and for the management of follow-up, toxicity, quality of life, palliative care, and supportive therapy. *Urol. Int.* <https://doi.org/10.1159/000511245> (2021).
- Heidenreich, A., Paffenholz, P., Nestler, T., Pfister, D. & Daneshmand, S. Role of primary retroperitoneal lymph node dissection in stage I and low-volume metastatic germ cell tumors. *Curr. Opin. Urol.* **30**, 251–257 (2020).
- Subramanian, V. S., Nguyen, C. T., Stephenson, A. J. & Klein, E. A. Complications of open primary and post-chemotherapy retroperitoneal lymph node dissection for testicular cancer. *Urol. Oncol.* **28**, 504–509 (2010).
- Rassweiler, J. J., Scheitlin, W., Heidenreich, A., Laguna, M. P. & Janetschek, G. Laparoscopic retroperitoneal lymph node dissection: does it still have a role in the management of clinical stage I nonseminomatous testis cancer? A European perspective. *Eur. Urol.* **54**, 1004–1015 (2008).
- Steiner, H., Leonhartsberger, N., Stoehr, B., Peschel, R. & Pichler, R. Postchemotherapy laparoscopic retroperitoneal lymph node dissection for low-volume, stage II, nonseminomatous germ cell tumor: first 100 patients. *Eur. Urol.* **63**, 1013–1017 (2013).
- Davol, P., Sumfest, J. & Rukstalis, D. Robotic-assisted laparoscopic retroperitoneal lymph node dissection. *Urology* **67**, 199 (2006).
- Pearce, S. M. *et al.* Safety and early oncologic effectiveness of primary robotic retroperitoneal lymph node dissection for nonseminomatous germ cell testicular cancer. *Eur. Urol.* **71**, 476–482 (2017).
- Overs, C. *et al.* Robot-assisted post-chemotherapy retroperitoneal lymph node dissection in germ cell tumor: Is the single-docking with lateral approach relevant?. *World J. Urol.* **36**, 655–661 (2018).
- Li, R. *et al.* Robotic postchemotherapy retroperitoneal lymph node dissection for testicular cancer. *Eur. Urol. Oncol.* <https://doi.org/10.1016/j.euo.2019.01.014> (2019).
- Eggerer, S. E. *et al.* Incidence of disease outside modified retroperitoneal lymph node dissection templates in clinical stage I or IIA nonseminomatous germ cell testicular cancer. *J. Urol.* **177**, 937–942 (2007) (**discussion 942–943**).
- Brierley, J., Gospodarovicz, M. K. & Wittekind, C. *TNM Classification of Malignant Tumours*, 8th edition. (John Wiley & Sons, Inc., Chichester, West Sussex, UK, Hoboken, NJ, 2017).
- Beck, S. D. W., Foster, R. S., Bihrl, R., Donohue, J. P. & Einhorn, L. H. Is full bilateral retroperitoneal lymph node dissection always necessary for postchemotherapy residual tumor?. *Cancer* **110**, 1235–1240 (2007).
- Heidenreich, A., Pfister, D., Witthuhn, R., Thüer, D. & Albers, P. Postchemotherapy retroperitoneal lymph node dissection in advanced testicular cancer: Radical or modified template resection. *Eur. Urol.* **55**, 217–224 (2009).
- Steiner, H., Peschel, R. & Bartsch, G. Retroperitoneal lymph node dissection after chemotherapy for germ cell tumours: Is a full bilateral template always necessary?. *BJU Int.* **102**, 310–314 (2008).
- Cheney, S. M., Andrews, P. E., Leibovich, B. C. & Castle, E. P. Robot-assisted retroperitoneal lymph node dissection: Technique and initial case series of 18 patients. *BJU Int.* **115**, 114–120 (2015).
- Donohue, J. P., Zachary, J. M. & Maynard, B. R. Distribution of nodal metastases in nonseminomatous testis cancer. *J. Urol.* **128**, 315–320 (1982).
- Dindo, D., Demartines, N. & Clavien, P.-A. Classification of surgical complications: A new proposal with evaluation in a cohort of 6336 patients and results of a survey. *Ann. Surg.* **240**, 205–213 (2004).
- Salazar, E. G. *et al.* Supportive care utilization and treatment toxicity in children with Down syndrome and acute lymphoid leukaemia at free-standing paediatric hospitals in the United States. *Br. J. Haematol.* **174**, 591–599 (2016).
- Rocco, N. R. *et al.* Primary robotic RPLND for nonseminomatous germ cell testicular cancer: A two-center analysis of intermediate oncologic and safety outcomes. *World J. Urol.* **38**, 859–867 (2020).
- Taylor, J. *et al.* Primary robot-assisted retroperitoneal lymph node dissection for men with nonseminomatous germ cell tumor: Experience from a multi-institutional cohort. *Eur. Urol. Focus* <https://doi.org/10.1016/j.euf.2020.06.014> (2020).
- Stepanian, S., Patel, M. & Porter, J. Robot-assisted laparoscopic retroperitoneal lymph node dissection for testicular cancer: Evolution of the technique. *Eur. Urol.* **70**, 661–667 (2016).
- Supron, A. D. *et al.* Primary robotic retroperitoneal lymph node dissection following orchiectomy for testicular germ cell tumors: A single-surgeon experience. *J. Robot Surg.* **15**, 309–313 (2021).
- Kamel, M. H., Littlejohn, N., Cox, M., Eltahawy, E. A. & Davis, R. Post-chemotherapy robotic retroperitoneal lymph node dissection: Institutional experience. *J. Endourol.* **30**, 510–519 (2016).
- Blok, J. M. *et al.* Clinical outcome of robot-assisted residual mass resection in metastatic nonseminomatous germ cell tumor. *World J. Urol.* <https://doi.org/10.1007/s00345-020-03437-z> (2020).
- Hiester, A., Nini, A., Arsov, C., Buddensieck, C. & Albers, P. Robotic assisted retroperitoneal lymph node dissection for small volume metastatic testicular cancer. *J. Urol.* **204**, 1242–1248 (2020).
- Umbreit, E. C. *et al.* Intraoperative and early postoperative complications in postchemotherapy retroperitoneal lymphadenectomy among patients with germ cell tumors using validated grading classifications. *Cancer* **126**, 4878–4885 (2020).
- Cary, C., Masterson, T. A., Bihrl, R. & Foster, R. S. Contemporary trends in postchemotherapy retroperitoneal lymph node dissection: Additional procedures and perioperative complications. *Urol. Oncol.* **33**(389), e15–21 (2015).
- Ghodoussipour, S. & Daneshmand, S. Surgical strategies for postchemotherapy testis cancer. *Transl. Androl. Urol.* **9**, S74–S82 (2020).
- Hsu, T.-W. *et al.* Clinical and pathologic factors affecting lymph node yields in colorectal cancer. *PLoS ONE* **8**, e68526 (2013).
- Calaway, A. C., Einhorn, L. H., Masterson, T. A., Foster, R. S. & Cary, C. Adverse surgical outcomes associated with robotic retroperitoneal lymph node dissection among patients with testicular cancer. *Eur. Urol.* **76**, 607–609 (2019).
- Albers, P., Hiester, A., Grosse Siemer, R. & Lusch, A. The PRIMETEST trial: Interim analysis of a phase II trial for primary retroperitoneal lymph node dissection (RPLND) in stage II A/B seminoma patients without adjuvant treatment. *J. Clin. Oncol.* **37**, 507–507 (2019).
- Daneshmand, S. *et al.* SEMS trial: Result of a prospective, multi-institutional phase II clinical trial of surgery in early metastatic seminoma. *J. Clin. Oncol.* **39**, 375–375 (2021).
- Groot, H. J. *et al.* Platinum exposure and cause-specific mortality among patients with testicular cancer. *Cancer* **126**, 628–639 (2020).
- Groot, H. J. *et al.* Risk of solid cancer after treatment of testicular germ cell cancer in the platinum era. *J. Clin. Oncol.* **36**, 2504–2513 (2018).
- Agrawal, V. *et al.* Adverse health outcomes among US testicular cancer survivors after cisplatin-based chemotherapy vs surgical management. *JNCI Cancer Spectr.* **4**, pkz079 (2020).

39. Fung, C. *et al.* Toxicities associated with cisplatin-based chemotherapy and radiotherapy in long-term testicular cancer survivors. *Adv. Urol.* **2018**, 8671832 (2018).
40. Gerdtsen, A. *et al.* Unilateral or bilateral retroperitoneal lymph node dissection in nonseminoma patients with postchemotherapy residual tumour? Results from RETROP, a population-based mapping study by the Swedish Norwegian Testicular Cancer Group. *Eur. Urol. Oncol.* <https://doi.org/10.1016/j.euo.2021.02.002> (2021).
41. Haarsma, R., Blok, J. M., van Putten, K. & Meijer, R. P. Clinical outcome of post-chemotherapy retroperitoneal lymph node dissection in metastatic nonseminomatous germ cell tumour: A systematic review. *Eur. J. Surg. Oncol.* **46**, 999–1005 (2020).

Acknowledgements

We thank Thomas Gebhardt, Department of Urology and Paediatric Urology, Saarland University Faculty of Medicine, Homburg/Saar, Germany for drawing and preparing the illustrations and pictures. We acknowledge support by the Deutsche Forschungsgemeinschaft (DFG, German Research Foundation) and Saarland University within the funding programme Open Access Publishing.

Author contributions

C.H.O.: manuscript writing and editing, data analysis, protocol/project development, patient operation. M.S.: manuscript editing, patient operation. L.C.P.: data collection, manuscript editing. M.Z.: data collection, manuscript editing. A.B.: data collection, manuscript editing. M.S.: manuscript editing, patient operation. S.S.: protocol/project development, patient operation, manuscript editing. J.H.: manuscript writing and editing, data acquisition, data analysis, protocol/project development, patient operation.

Funding

Open Access funding enabled and organized by Projekt DEAL.

Competing interests

Stefan Siemer is a proctor for Intuitive Surgical Inc. There are no further conflicts of interest or competing interest for the other authors.

Additional information

Correspondence and requests for materials should be addressed to J.H.

Reprints and permissions information is available at www.nature.com/reprints.

Publisher's note Springer Nature remains neutral with regard to jurisdictional claims in published maps and institutional affiliations.



Open Access This article is licensed under a Creative Commons Attribution 4.0 International License, which permits use, sharing, adaptation, distribution and reproduction in any medium or format, as long as you give appropriate credit to the original author(s) and the source, provide a link to the Creative Commons licence, and indicate if changes were made. The images or other third party material in this article are included in the article's Creative Commons licence, unless indicated otherwise in a credit line to the material. If material is not included in the article's Creative Commons licence and your intended use is not permitted by statutory regulation or exceeds the permitted use, you will need to obtain permission directly from the copyright holder. To view a copy of this licence, visit <http://creativecommons.org/licenses/by/4.0/>.

© The Author(s) 2021, corrected publication 2021